

PAPER • OPEN ACCESS

Apparent Diffusion Coefficient of Diffusion Weighted Imaging have Strong Correlation with the Malignancy Grading of Intracranial Tumor

To cite this article: AD Sensusiaty 2020 *J. Phys.: Conf. Ser.* **1445** 012019

View the [article online](#) for updates and enhancements.

You may also like

- [Task-based evaluation of segmentation algorithms for diffusion-weighted MRI without using a gold standard](#)
Abhinav K Jha, Matthew A Kupinski, Jeffrey J Rodríguez et al.
- [Energy resolution of gas ionization chamber for high-energy heavy ions](#)
Yuki Sato, Atsushi Taketani, Naoki Fukuda et al.
- [OLED lightings with optical feedback for luminance difference compensation](#)
D K Shin and J W Park



ECS
The
Electrochemical
Society
Advancing solid state &
electrochemical science & technology

DISCOVER
how sustainability
intersects with
electrochemistry & solid
state science research

Apparent Diffusion Coefficient of Diffusion Weighted Imaging have Strong Correlation with the Malignancy Grading of Intracranial Tumor

Sensusiati AD

Medical Faculty of Universitas Airlangga, Airlangga University Hospital, Surabaya

anggraini-d-s@fk.unair.ac.id / radiologigdc1@gmail.com

Abstract

Background and purpose: Accurate imaging diagnosis before surgery is fundamental to determine whether a tumor is benign or malignant. Diagnosis only from structural MRI is not specific. However, the diffusivity of the benign and malignant lesion is different and could be measured by ADC. The Apparent Diffusion Coefficient (ADC) values are calculated automatically by application software and displayed as a parametric map that reflects the degree of diffusion of water molecules through different tissues. The purpose of this study was to analyze the correlation between Diffusion-Weighted Magnetic Resonance Imaging (DWI) and Apparent Diffusion Coefficient (ADC) values with histopathology grading of brain tumors.

Material and methods: Pathology reports of intracranial tumor material were correlated with diffusivity of the tumor, and the ADC values, performed within 2 years of post-operative histopathology study. A freehand closed ROI out-lined the whole visible tumor on the most representative slice of ADC maps defined as the slice with the maximum diameter of the solid neoplastic component. ADC values were taken from 2 averages of 2 ROIs. Spearman Correlation test was used to assess the correlation between ADC values with the malignancy grading of the tumor.

Result: Low-grade malignant tumors show facilitated diffusion with high ADC values, and high-grade malignant tumors show restricted diffusion with low ADC values. The mean ADC value of Grade I tumor is $1.0799 \pm 0.2356 \times 10^{-3} \text{ mm}^2/\text{sec}$ and the mean ADC value of Grade IV tumor is $0.6798 \pm 0.23729 \times 10^{-3} \text{ mm}^2/\text{sec}$. The Spearman correlation test between ADC value and histopathology result shown $r = -0.536$ and $p = 0.000$ and the test result for ADC value and DWI shown $r = -0.706$ and $p = 0.000$ (Sig. 0.05).

Conclusion: There was strong correlation between DWI and ADC values with histopathology grading of intracranial tumors.

1. Introduction

Accurate diagnosis in cerebral tumor plays an important role in determining the optimal therapeutic strategy. The nature and grading of tumors determine the therapeutic approach during the preoperative, intra-operative management, and postoperative. Conventional MRI had sensitivity, specificity, PPV, and NPV of conventional MRI to determine high-grade glioma was 72.5%, 65.0%, 86.1%, and 44.1% [1]. Therefore, at this time developed advanced MRI techniques that can help improve the accuracy of preoperative diagnosis of cerebral tumor histopathology [2].



Diffusion Weighted Imaging (DWI) MRI is an advanced technique that currently is developed as a method of assessment of cerebral tumor. DWI showed contrasting images that depend on the movement of water molecules, which can substantially altered by multiple abnormalities, so that the characteristics of DWI profiles can be used to identify and characterize intracranial lesions [3]. Cellularity of the tumor, the extracellular matrix and the integration of the cell membrane can cause variations in the mobility of water molecules in the tumor [4] with a degree of restriction of diffusion of water molecules in the tumor will be correlated with the density of tissue cells and the extracellular matrix [5]. In the malignant tumor cells generally have a large nucleus and indicates the level of high cell densities [6].

Apparent diffusion coefficient (ADC) is DWI quantitative parameters that describe the movement of the diffusion of water molecules in various tissues. ADC values correlated with tumor cellularity [7], and proved to have a reciprocal relationship with cell density [8]. Most research suggests that malignant tumors have lower ADC values of benign tumors [6]. Such conditions indicate that DWI can be used to differentiate between malignant and benign cerebral tumors.

Up until now, Dr. Soetomo hospital has not had the DWI profiles and ADC values were correlated with histopathological examination results. Therefore this research conducted to known the relationship of DWI profile and the measurements of ADC value on a cerebral tumor with histopathological results in patients with cerebral tumor after surgery.

2. Material and Method

This study used a retrospective method based on secondary data to determine the profile of DWI, ADC values with the histopathology grading and type. Samples derived from patients at the Dr. Soetomo hospital in January 2013 - December 2014 and match with the inclusion criteria.

The inclusion criteria include:

- Patients with cerebral intra axial and extra axial tumors
- Patients medical records complete and accessible
- Had done MRI head with contrast and DWI sequence in Dr. Soetomo hospital Surabaya
- Has performed surgery and histopathological examination of tumor tissue in Dr. Soetomo hospital.

The data were statistically analyzed by Spearman correlation test with 95% CIs and considered significant if $p < 0.05$.

3. Result

3.1. Sample Demographics

From 90 samples, 66,67% are female. The age of the sample is between 1-62 years old with the means of the age is $33,59 \pm 17,37$ years old.

Table 1. Sample Demographics

Gender	
Male	40%
Female	60%
Age	
Maximum	78
Minimum	6
Mean	48,15
Std. Deviation	14,28

3.2. DWI Profile of Cerebral Tumor

The DWI profile of cerebral tumor can be divided into three categories, facilitative, restrictive, and unrestricted. There is no unrestricted case found and the mostly found cases are facilitative (74,4%).

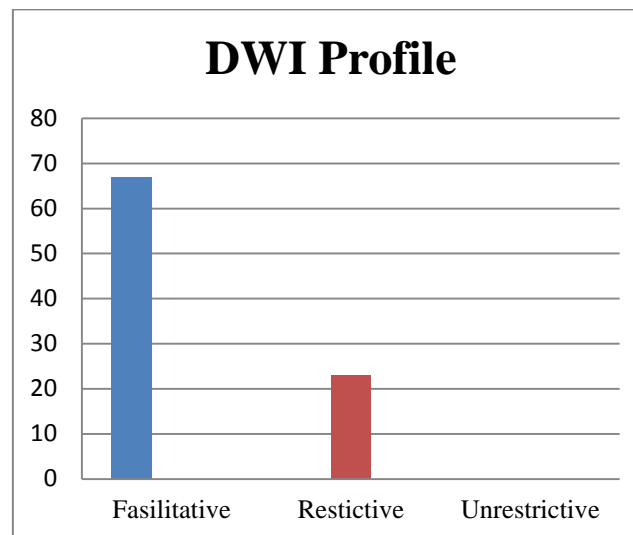


Fig 1. DWI profile of cerebral tumor

3.3. ADC Value

The calculating result of ADV value of patients with cerebral tumor showed the lowest ADC value is $0.36 \times 10^{-3} \text{ mm}^2/\text{sec}$ and the highest ADC value is $2.12 \times 10^{-3} \text{ mm}^2/\text{sec}$. The mean of the ADC value is $0.983 \pm 0.304 \times 10^{-3} \text{ mm}^2/\text{sec}$

Table 2. ADV Value Descriptive Statistic

	N	ADC value x $10^{-3} \text{ mm}^2/\text{sec}$			
		Minimum	Maximum	Mean	Std. Deviation
ADC Value	90	0.36	2.12	0.983	0.304

3.4. Histopathology Tumor

The results of histopathological examination of tumor tissue were categorized by 2007 WHO classification which can be categorized in four grades, Grade I, Grade II, Grade III, and Grade IV (9). The most common to be found is Grade I (62,2%) and the least common is Grade III (6,7%).

Table 3. Cerebral Tumor WHO Grading

WHO Grade	Frequency	Percentage (%)
Grade I	56	62,2
Grade II	11	12,2
Grade III	6	6,7
Grade IV	17	18,9
Total	90	100

3.5. Statistical Analyzed

3.5.1. DWI Profile and ADC Value

The means of ADC value of facilitative diffusion on cerebral tumor is $0.643 \pm 0.152 \times 10^{-3} \text{ mm}^2/\text{sec}$ and at diffusion restriction is $1.099 \pm 0.251 \times 10^{-3} \text{ mm}^2/\text{sec}$. The means of ADC value of facilitative diffusion is higher than at the diffusion restriction.

The result of statistical test shown $r=0.706$ and $p=0.000$ (Sig. 0.05). It means that statistically there is a significant correlation between DWI profile and ADC value.

Table 4. Characteristics of DWI profiles with ADC values

DWI Profile	ADC value $\times 10^{-3} \text{ mm}^2/\text{sec}$			
	Minimum	Maximum	Mean	Std. Deviation
Facilitative	0.36	1.03	0.643	0.152
Restrictive	0.77	2.12	1.099	0.251

3.5.2. WHO Grade and ADC Value

Among the four WHO grades, Grade I has the highest means of ADC value while Grade IV has the lowest. There is a tendency for ADC values to decrease as the WHO Grade gets higher.

Table 5. Characteristics of WHO grade with ADC values

WHO Grade	ADC value $\times 10^{-3} \text{ mm}^2/\text{sec}$			
	Min	Max	Mean	Std. Deviation
I	0.59	1.80	1.08	0.24
II	0.48	1.41	0.93	0.26
III	0.69	2.12	1.03	0.54
IV	0.36	1.33	0.68	0.24

The result of statistical test shown $r=-0.536$ and $p=0.000$ (Sig. 0.05). It means that statistically there is a significant correlation between WHO Grade and ADC value.

4. DISCUSSION

4.1. Correlation of DWI Profile and ADC Value

DWI shows different image contrast from conventional MRI techniques, where DWI shows contrast proton mapping that reflects the diffusion of water molecules. DWI is done with a pulse sequence that is capable of measuring the displacement of water molecules at very short distances. The diffusion of water molecules becomes much slower (diffusion restriction) or faster (facilitative diffusion) under certain pathological conditions compared to normal brain parenchyma.

In this research, there was a significant relationship between DWI profile and ADC value ($p = 0.000$). The mean ADC values in the facilitative diffusion DWI profile on cerebral tumors were $0.643 \pm 0.152 \times 10^{-3} \text{ mm}^2/\text{sec}$ and in the DWI profile the diffusion restriction was $1.099 \pm 0.251 \times 10^{-3} \text{ mm}^2/\text{sec}$. In other literature ADC values less than $1.0-1.1 \times 10^{-3} \text{ mm}^2/\text{sec}$ indicate the restriction of the diffusion of water molecules [10].

4.2. Correlation of WHO Grade and ADC Value

MRI is a highly sensitive imaging modality for evaluating cerebral tumors, but conventional MRI has limitations to differentiate histopathology types of most cerebral tumors.

Although ADC values of each type of tumor histopathology show an overlapping value and in Kono et al's study reported that ADC values in some cases cannot be used to differentiate tumor histopathology types [8]. In this study statistically, there was a significant relationship between DWI profile and ADC value with histopathological type of tumor tissue ($p = 0,000$).

This study shown there is a tendency for ADC values to decrease as the WHO Grade gets higher. In accordance with Kono et al. ($n = 56$) where the higher ADC values point to LGG (WHO I, II) and lower ADC values lead to HGG (WHO III, IV) [8].

5. CONCLUSION

There were significant correlation between DWI and ADC with grading and histopatological type of intracranial tumors

References

- [1] Law M, Yang S, Wang H, Babb J, Johnson G, Cha S, et al. Glioma grading: sensitivity, specificity, and predictive values of perfusion MR imaging and proton MR spectroscopic imaging compared with conventional MR imaging. *AJNR Am J Neuroradiol*. 2003 November-December; 24(10): p. 1989-1998.
- [2] Svolos P, Kousi E, Kapsalaki E, Theodorou K, Fezoulidis I, Kappas C, et al. The role of diffusion and perfusion weighted imaging in the differential diagnosis of cerebral tumors: a review and future perspectives. *Cancer Imaging*. 2014 April; 14(1): p. 20.
- [3] Schaefer P, Grant P, Gonzalez R. Diffusion weighted MR imaging of the brain. *Radiology*. 2000; 222: p. 410-418.
- [4] Le Bihan D, Breton E, Lallemand D, Aubin ML, Vignaud J, Laval-Jeantet M. Separation of diffusion and perfusion in intravoxel incoherent motion MR imaging. *Radiology*. 1988 August; 168(2): p. 497-505.
- [5] Gauvain K, McKinstry R, Mukherjee P, Perry A, Neil J, Kaufman B, et al. Evaluating pediatric brain tumor cellularity with diffusion-tensor imaging. *AJR Am J Roentgenol*. 2001 August; 177(2): p. 449-454.
- [6] Bozgeyik Z, Onur MR, Poyraz AK. The role of diffusion weighted magnetic resonance imaging in oncologic setting, Turkey. *Quant Imaging Med Surg*. 2013 October; 3(5): p. 269-278.
- [7] Sugahara T, Korogi Y, Kochi M, Ikushima I, Shigematu Y, Hirai T, et al. Usefulness of diffusion-weighted MRI with echo-planar technique in the evaluation of cellularity in gliomas. *J Magn Reson Imaging*. 1999 January; 9(1): p. 53-60.
- [8] Kono K, Inoue Y, Nakayama K, Shakudo M, Morino M, Ohata K, et al. The role of diffusion-weighted imaging in patients with brain tumors. *AJNR Am J Neuroradiol*. 2001 June-July; 22(6): p. 1081-1088.
- [9] Louis DN, Ohgaki H, Wiestler OD, Cavenee WK, Burger PC, Jouvet A, et al. The 2007 WHO Classification of Tumours of the Central Nervous System. *Acta Neuropathol*. 2007 August; 114(2): p. 97-109.
- [10] Haaga J, Boll D. CT and MRI of the Whole Body. 5th ed. Dogra V, Forsting M, Gilkeson R, Ha KH, Sundaram M, editors. China: Mosby Elsevier; 2009.